

Letter to Bruce Oxley,
The Editor,
Scottish Dental Magazine
bruce@connectcommunications.co.uk

Dear Mr Oxley,

We, the undersigned have, for many years, written and spoken against some of the destructive excesses of modern, supposedly “restorative” or “cosmetic” dental practice, one as a concerned Scottish GDP (JC), and the other as a consultant in restorative dentistry (MK). We had thought that such destructive methods were becoming less prevalent in modern dentistry, but apparently not so. We, therefore, write to challenge several of the points expressed in one of your recent articles. This peculiar article demonstrated **mild** upper anterior tooth surface loss with a **mild postural** Class 3 adaptive position, which is often found when the loss of upper incisor height has been due to **chemical erosion**. We disagree strongly that this picture showed “**severe wear**” as was stated incorrectly in that article.

As a general rule in tooth wear assessment, if the crown heights of the **upper** anterior teeth have been preferentially shortened, but the height of the **lower** teeth have not been equivalently affected, experienced clinicians can usually be fairly sure that the upper tooth surface loss has been caused mainly by **chemical erosion**. This is because the lower teeth are generally spared from most of the damage caused by the damaging erosive acid fluids, during EITHER extrinsic or intrinsic acid attacks, by the protective action of the tongue. The tongue lies over the lower teeth during the swallowing of acidic fluids, or during any sort of regurgitation and thereby keeps most of the erosive acids away from the lower teeth but allowing the damaging acids to attack the top teeth and thereby shortening them so that their height to width ratios are reduced disproportionately and they then look “short and wide”.

In your recently published case report, the heights of the upper anteriors appeared to have been preferentially reduced to the extent of them being about the same as their width. By way of contrast, the opposing **lower teeth** appeared still to be a normal shape and have a significantly greater height than their width-which is usually the case in healthy unworn lower incisor teeth.

This contrast in the opposing dental arches clearly pointed to **chemical** erosion as being the most likely explanation for this particular case presentation, because, if the tooth surface loss had been due to **physical** attrition, then the much smaller lower incisors would have been worn preferentially, or at the very least equivalently, to match the tooth surface loss apparent at the upper incisors. By way of illustration of this important differential diagnostic point, two images from a DIFFERENT case, this time actually showing SEVERE preferential tooth surface loss are shown below.

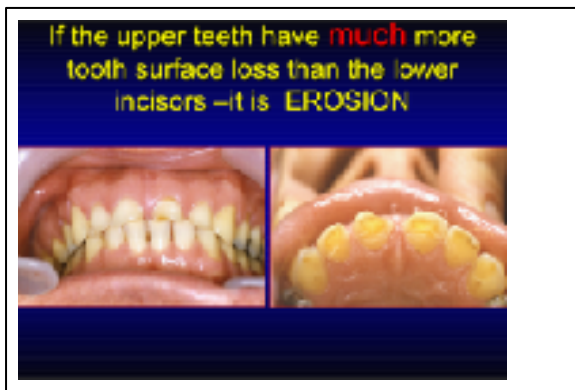

Figure 1 The tooth surface loss is greater at the upper teeth so that they appear shorter and wider

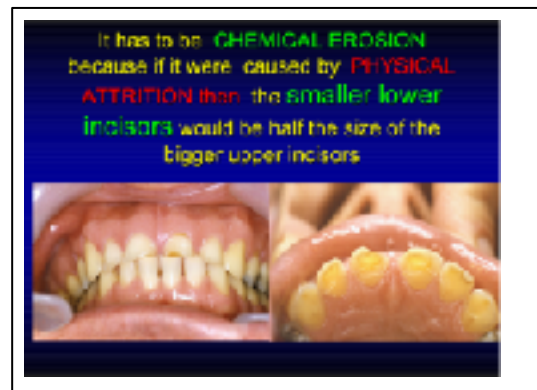


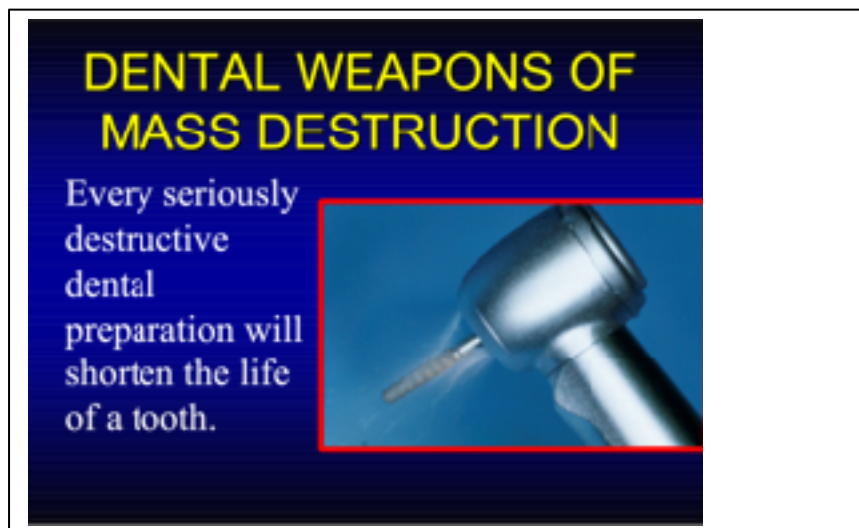
Figure 2 The lower incisors have a normal height to width ratio

Sadly, in our view, it is not infrequent to still see this sort of failure of accurate diagnosis of the probable aetiology for shortened upper teeth before then proceeding as shown in that recent case report with what, in our sincerely held opinion, was an unnecessarily destructive treatment plan involving multiple ceramic veneered full coverage crowns for this mild wear problem.

Sadly, many such aggressive cases appear increasingly in un-refereed, commercially driven trade journals, apparently being written and published for some motives other than to make teeth healthier or longer lasting. We guess that it is vaguely possible that such case reports get published because of various “advertorial” or other unstated commercial

interests. Many of these cases appear to us to be sometimes done for rather questionable “cosmetic” benefit or to conform to some unproven, or unscientific, occlusal belief system sometimes involving articulators of varying complexity being used in order to treat wear problems.

Parts of the Hippocratic Oath include “Firstly, or most importantly, do no harm” but also exhort that “Extreme remedies should be reserved for extreme diseases”. Mild tooth surface loss is not an extreme disease. Elective removal of much residual sound tooth tissue, such as shown in your case report, does do structural and other biologic harm often involving processes that are not benign, not trivial and not reversible. High speed drills with diamond burs are dental weapons of mass destruction and every seriously destructive preparation of an already worn tooth will probably shorten its life although the ceramic veneered crowns may well look pretty at the start of their life as shown in your case. However, that aesthetic or biologic picture will probably look worse in twenty or thirty years’ time with a poor “fall-back position”, sadly, for the patient.



We honestly believe that most experienced dentists when treating **mild wear** would not remove vast amounts of residual sound tooth tissue from their own daughter’s teeth¹, from a colleague’s teeth nor indeed have it removed voluntarily from their own teeth. There is no articulator system in the world that can compensate a tooth for hazarding its pulpal health with a full coverage crown preparation (Felton et al 1987),² or for the loss of 62-73% of its load bearing structure, which has been shown by Edelhof and Sorenson (2002)³ to be what happens with full coverage

preparations for ceramic veneered crowns as shown in one of your recent articles.

Tooth structure removal associated with various preparation designs for anterior teeth

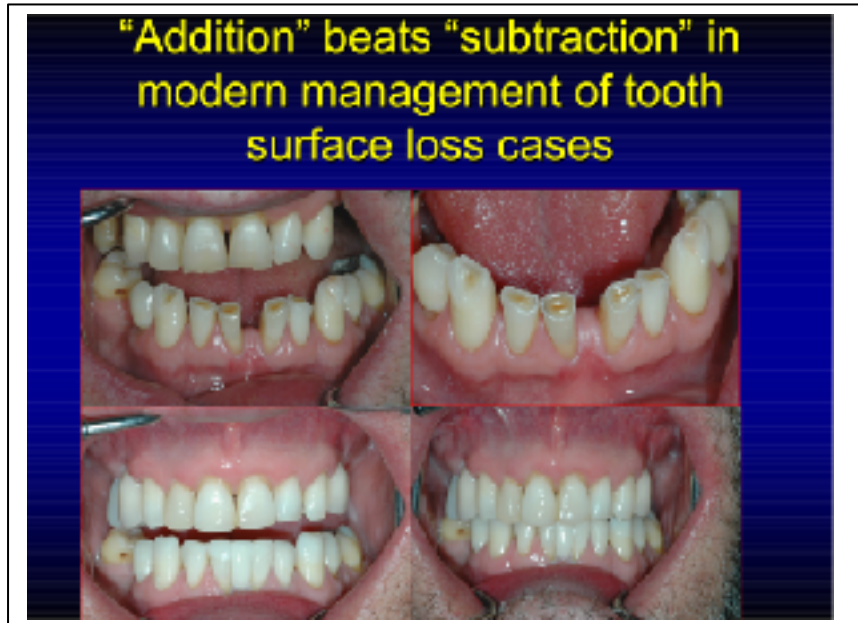- 63% to 72% of the coronal tooth tissue lost with All Ceramic or PFM preparations
- Up to 30% of the coronal tooth tissue destroyed by extended porcelain veneer or resin bonded crown preparations
- Edelhoff D and Sorensen JA
- J.Prosth. Dent 2002 87(5) 503-509

We feel strongly that many experienced dentists would recognise that most sane patients would reject the destructive options if those known figures mentioned above were explained to them in advance, in order to obtain their informed consent for the dental destruction illustrated in your case report, especially given that there were other viable, non destructive options available to them. For instance, instead of this irreversibly damaging porcelain pornography,⁴ some direct composite bonding applied to the upper incisors to lengthen them and composite additions to the canines to reintroduce canine guidance, would have predictably changed this sort of “Pseudo Class 3” in to a Class One occlusion in relatively short order, but without taking any pulpal risks or doing any structural damage to these teeth.

If, in this case, the **colour** happened to have been an important issue for the patient then, again in our view, conventional night guard vital bleaching with 10% carbamide peroxide could have sorted out that perceived colour problem safely and predictably in advance of some non-destructive direct resin composite bonding being done to change the **shapes** of the teeth.

Such an **additive rather than destructive approach** to tooth surface loss would have sorted out these apparent tooth surface loss problems, probably in one visit, with minimal biologic or structural damage being done to the shortened upper teeth. Direct resin composite bonding would probably have been predictable, because the composite resin material

indicated here only needed to be resistant to further acid attack, the source of which should have been determined prior to treatment. By way of contrast to your destructive case report a different case with moderate wear is shown below being treated with an “additive approach” rather than a “subtractive” one .



In spite of these alternative, biologically sensible approaches being proven ^{5,6,7} and readily available, we were very perturbed to see yet another recent case report using an outdated and grossly destructive full coverage crown approach to these mainly structurally sound upper teeth to produce a questionable biologic and “cosmetic” result under the guise of using a semi adjustable articulator. That air rotor attack did more damage to them in one visit than many previous, or successive years of wear might have caused, if the erosive acid attacks had been identified in order to eliminate them.

This sort of aggressively destructive treatment for the apparently mild tooth surface loss was and remains, in our sincerely held opinion, the wrong treatment from a biologic perspective. Here it resulted in about 40 more years of structural damage being done by a dental bur in a short period of time. This was something that we feel can not now be justified ethically, or biologically, given our modern understanding of the longer term biological costs of damaging previously sound teeth.

The adaptive class III shown here was probably just that –adaptive- and in our experience this occurs as a result of slow hard tissue loss and the periodontal ligament mechano- receptors programming the neuro-

musculature around the mandible to move the teeth forward more to an edge to edge relationship in order to improve function. However, once one opens the anterior vertical dimension with direct resin, or other restorations, the lower teeth usually move back quite soon in to Class 1 as the condyles move upwards and backwards quite quickly, and then other tooth movements occur to establish a new intercuspal position over time.^{5,6,7} Localised increase in anterior vertical dimension is sometimes described as being a “Dahl principle,”⁶ but adaptation by dentate patients to increasing vertical dimension with restorations, was described by Anderson as long ago as 1962.⁹

In our opinion, given the now well documented evidence for these scientifically proven minimally destructive approaches, it is very worrying for the profession at large and the patients in general to see this sort of old fashioned iatrogenic damage still being published under the guise of using articulators to optimise the subsequent crown restorations. This sort of destructive preparation for crowns in wear cases was common in the 1970's⁸ and 1980's when that was all that was available for us to treat this sort of problem. The sort of treatment shown in your recent article pre- dated predictable adhesive dentistry, or our understanding of differential diagnosis of causes of tooth surface loss, or when treating various sorts of problems without further damaging the teeth was rather less well developed than it is now^{10,11}.

Yours faithfully,

John Craig, Falkirk
Martin Kelleher, London

References :

1. Burke FJ, Kelleher MGD . **The `Daughter Test` in elective esthetic dentistry** J Esthet E Restor Dent. 2009; 21(3) : 143-6
2. Felton D, Madison S, Kanoy E et al. Long term effects of crown preparations on pulp vitality. *J Dent Res* 1989; 68:1009: Abstract 1139.
3. Edelhoff D, Sorensen JA. Tooth structure removal associated with various preparation designs for anterior teeth. *J Prosthet Dent*. 2002 May;87(5):503-9.
- 4 Kelleher M. Porcelain pornography. *Fac Den J* 2011; 2: 134-141
5. Poyser NJ, Briggs PF, Chana HS, et al
The evaluation of direct composite restorations for the worn mandibular anterior dentition - clinical performance and patient satisfaction.

J Oral Rehabil. 2007 May;34(5):361-76.

- 6 Gulamali AB, Hemmings KW, Tredwin CJ, Petrie A.
Survival analysis of composite Dahl restorations provided to manage
localised anterior tooth wear (ten year follow-up).

[Br Dent J](#). 2011 Aug 26;211(4):E9. doi: 10.1038/sj.bdj.2011.683.

7. Al-Khayatt AS, Ray-Chaudhuri A, Poyser et al
J Oral Rehab 2013 May;40(5):389-401. doi: 10.1111/joor.12042. Epub
2013 Mar 15.

Direct composite restorations for the worn mandibular anterior dentition:
a 7-year follow-up of a prospective randomised controlled split-mouth
clinical trial.

8Shillingburg HT ,Hobo S,Whitsett
Fundamentals of Fixed Prosthodontics
Quintessence Publishing Co.1978 pages 67,111

- 9.Anderson DJ Tooth movement in experimental malocclusion Archs.
Oral Biol. p.7-16

- 10.Burke FJT,,KelleherMGD,,Wilson N,,Bishop KB (2011)
Introducing the concept of pragmatic esthetics with special reference to
the treatment of tooth wear J.Esthet .Restor.Dent.23 (5) 1-17

- 11.Kelleher MGD Bomfin D,Austin RS (2012) Biologically based
restorative management of tooth wear Int J.Dent .ID 742509